

Morphological Variations of the Tricipital Aponeurosis and Its Clinical Significance: A Cross-sectional Cadaveric Study

B ANISHA¹, S SYAMLY², SV UMA³

ABSTRACT

Introduction: The radial nerve is commonly injured during posterior approach humerus surgeries, making it crucial for surgeons to identify and preserve the nerve. The tricipital aponeurosis (TA) serves as a reliable landmark for identifying the radial nerve during these procedures.

Aim: This study aimed to investigate the different shapes and patterns of the TA and their relationship with the radial nerve, as well as their clinical significance.

Materials and Methods: A cross-sectional observational cadaveric study was conducted in the Department of Anatomy, Dr. Chandramma Dayanand Sagar Institute of Medical Education and Research (CDSIMER), a unit of Dayanand Sagar University (DSU), Bengaluru, Karnataka, India, from January 2022 to April 2022. A total of 40 arms from 20 adult cadavers

obtained from CDSIMER were examined. The TA was assessed to record variations in its shape and classified accordingly. The distance of the radial nerve from the point of confluence was measured for different types. Vernier calipers were used for all measurements. The collected data was analysed using the Statistical Package for the Social Sciences (SPSS) version 16.0, and paired two-tailed Student's t-test was performed.

Results: The classical type A was observed in 32 (80%) of the specimens. The mean distance of the radial nerve from the point of confluence of the TA was 30.58 ± 4.29 mm on the right side and 31.27 ± 4.48 mm on the left side, with a p-value of 0.621.

Conclusion: Knowledge of the different shapes of the TA and its distance from the radial nerve can assist surgeons in creating a safe zone during various procedures, thereby preventing radial nerve injuries.

Keywords: Humerus fractures, Point of confluence, Radial nerve

INTRODUCTION

The triceps brachii muscle dominates the posterior compartment of the arm. It originates from three heads: the long head, lateral head, and medial head. The long head arises from the infraglenoid tubercle of the scapula, the lateral head from the oblique ridge along the lateral lip of the spiral groove, and the medial head from the posterior surface of the humerus below the spiral groove. It inserts into the posterior part of the upper surface of the olecranon process. Before insertion, it forms a broad fibrous expansion known as the tricipital aponeurosis (TA), which is a shiny white-colored aponeurosis extending from the convergence of the long and lateral heads of the triceps muscle to the subcutaneous part of the olecranon process of the ulna [1].

Humeral shaft fractures account for 3% of all treated fractures and have an incidence of 13 per 100,000 per year [1]. Fractures involving the distal third of the humerus require surgical intervention for skeletal stability [2,3]. Various approaches can be used to access the fracture shaft, such as anterior, lateral, anterolateral, or posterior triceps splitting approaches. Among these, the posterior approach provides excellent exposure to the humeral diaphysis and distal metaphysis. However, the posterior triceps splitting approach may result in intraoperative injury to the radial nerve [4]. Iatrogenic injury to the radial nerve occurs in approximately 0-10% of patients during intraoperative fixation of fractures, with permanent nerve damage occurring in 0-3% of patients [4,5]. The radial nerve is highly susceptible to injury due to its long and tortuous course and proximity to the periosteum. The proximal apex of the TA has been considered the most reliable soft tissue landmark for identifying the radial nerve intraoperatively in such injuries [6].

The radial nerve is the largest branch of the brachial plexus and is the continuation of the posterior cord. It carries fibers from C5, C6, C7, C8, and T1. The nerve enters the spiral groove between the long and medial heads of the triceps and runs downward and laterally along the groove between the lateral and medial heads of

the triceps. It pierces the lateral intermuscular septum at the level of the middle and distal thirds of the humerus. The radial nerve is most prone to injury in the distal third of the arm [5]. As the TA serves as an important landmark to avoid such injuries, it is necessary for orthopaedic surgeons to be aware of the morphology and morphometry of the TA [6]. Although the relationship between the TA and the radial nerve has been studied by various authors [5,6], the shape and morphometric measurements of the TA have not been described in detail. Additionally, different types of TA have not been extensively studied in different populations.

With this background, the study was conducted with the aim of investigating the different shapes and patterns of the TA and measuring the distance of the radial nerve from the apex of the TA.

MATERIALS AND METHODS

This cross-sectional observational cadaveric study was conducted at the Department of Anatomy, Dr. Chandramma Dayanand Sagar Institute of Medical Education and Research (CDSIMER), Unit of Dayanand Sagar University (DSU), Bengaluru, Karnataka, India, from January 2022 to April 2022. Ethical clearance was obtained from our Institutional Ethical Committee (CDSIMER/MR/0073IEC/2023). Consent for using the cadavers for research purposes was obtained during the body donation process.

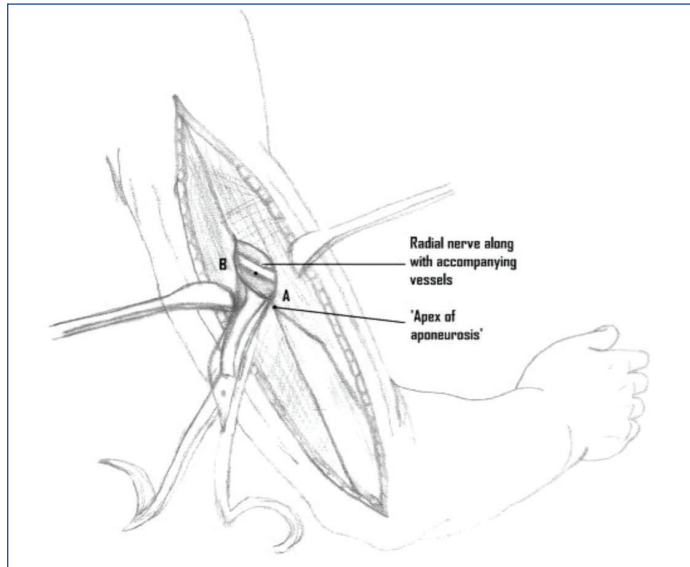
Inclusion criteria: A total of 40 limbs from 20 cadavers between the ages of 40-60 years were included.

Exclusion criteria: Limbs displaying any gross malformation, deformity, or signs of previous injury or fractures were excluded.

Study Procedure

Each of the cadavers was preserved using a 10% formalin solution following standard fixation methods. The limbs were dissected while maintaining a 90° flexion. A midline incision was made from the tip of the acromion process to the olecranon process. The tricipital aponeurosis

(TA) was observed as a shiny white-coloured aponeurosis extending from the junction of the long and lateral heads of the triceps muscle to the subcutaneous part of the olecranon process [Table/Fig-1] [5].




[Table/Fig-1]: Showing points of measurement-Apex of TA and radial nerve [5].

The intramuscular septum between the long and lateral heads of the triceps muscle was identified. The point where this septum intersected with the triceps aponeurosis was identified. The TA formed two apices: a proximal apex and a distal apex. The proximal apex, or main apex, was considered the point of confluence where both heads of the triceps muscle met. Blunt dissection was performed at a level of 1.5 inches from the apex of the TA, and the radial nerve was identified lying against the periosteum of the posterior surface of the humerus. Different patterns of the aponeurosis were classified according to Patra A et al. [7].

- Type A: Classically seen as a triangular proximal apex.
- Type B: Tongue-shaped or blunt proximal apex.
- Type C: Bifurcated or dual proximal apex.
- Type D: Absence of TA.

The distance from the proximal apex to the radial nerve was measured [Table/Fig-2]. All measurements were taken twice using Vernier calipers (with a resolution of 0.01) and the average of the two readings was recorded as the final measurement.



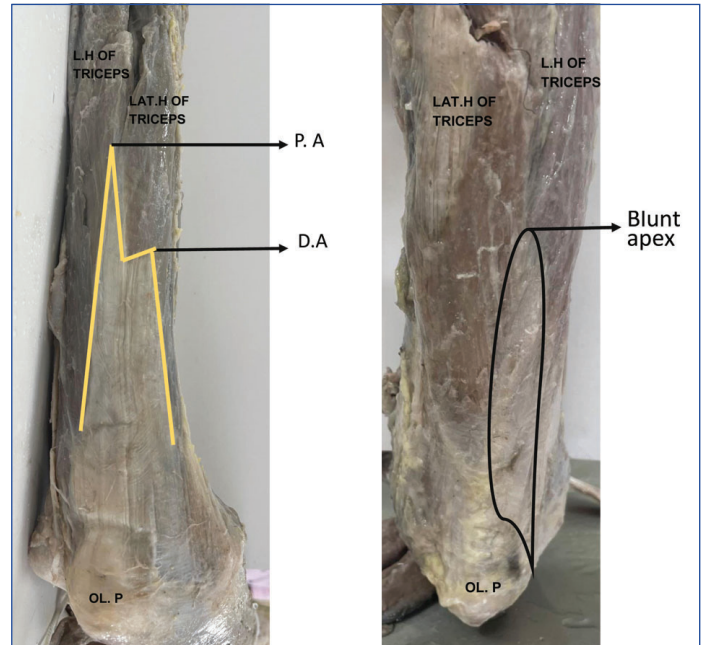
[Table/Fig-2]: Showing points of measurement from apex of TA to radial nerve. A: Radial nerve; B: Apex of tricipital aponeurosis; L.H: Long Head of Triceps; LAT.H: Lateral Head of Triceps; OL.P: Olecranon Process

STATISTICAL ANALYSIS

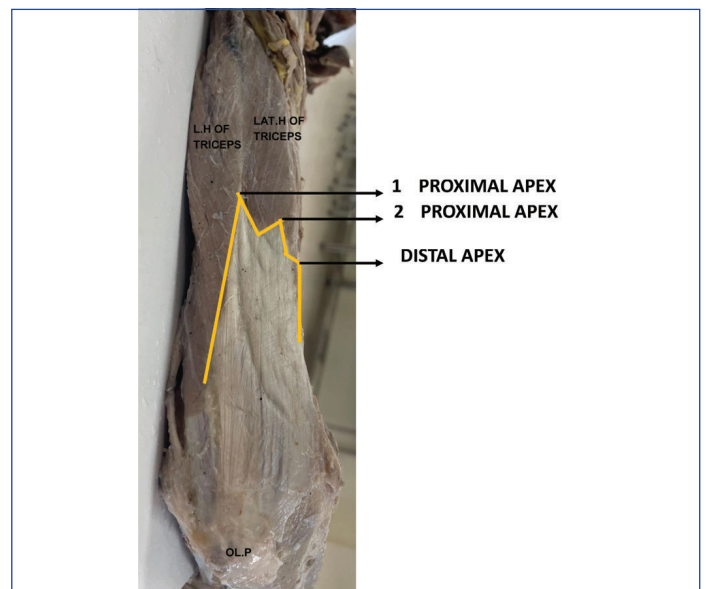
The collected data were analysed using SPSS version 16.0. A paired, two-tailed Student's t-test was performed.

RESULTS

The classical variant or Type-I was observed in 32 (80%) cases, Type-II in 6 (15%) cases, and Type-III in 2 (5%) cases [Table/Fig-3,4]. The mean distance of the radial nerve (RN) from the point of confluence of TA was 30.58 ± 4.29 mm on the right side and 31.27 ± 4.48 mm on the left side, with a p-value of 0.621 [Table/Fig-5].



[Table/Fig-3]: Showing classical Type-I pattern and Type-II pattern of TA. (Images from left to right) L.H: Long head of triceps; LAT.H: Lateral head of triceps; OL.P: Olecranon process; P.A: Proximal apex; D.A: Distal apex



[Table/Fig-4]: Showing Pattern-III- bifurcated proximal apex. LH: Long head of triceps; LAT.H: Lateral Head of Triceps; OL.P: Olecranon process

Mean distance of radial nerve from point of confluence	Right-side (mm)	Left-side (mm)	Total (mm)	p-value
Type-I	30.38 ± 4.29	30.50 ± 4.32	30.44 ± 4.15	0.482
Type-II	31.93 ± 4.09	31.81 ± 3.92	31.87 ± 4.2	0.631
Type-III	36.93 ± 2.54	35.55 ± 3.12	36.87 ± 0.81	0.681
In all the 3 patterns	30.58 ± 4.29	31.27 ± 4.48	30.10 ± 4.38	0.621

[Table/Fig-5]: Mean distance of radial nerve from the point of confluence in all the patterns.

The mean distance of the RN from the point of confluence was 30.44 ± 4.15 mm, 31.87 ± 4.2 mm, and 36.87 ± 0.81 mm for Patterns I, II, and III, respectively [Table/Fig-5].

DISCUSSION

The radial nerve is closely related to the periosteum while running through the radial groove in the extensor compartment of the arm. Locating and preserving the radial nerve is vital during humerus fractures. Previously, several authors have studied the relationship of the radial nerve to various bony landmarks such as the olecranon process, lateral epicondyle, and acromion process [6, 8, 9]. However, the triceps apex (TA) is considered more reliable than all these bony landmarks as it is less likely to be deranged during displaced fractures of the humerus. Despite the common occurrence of iatrogenic injuries to the radial nerve in the posterior approach, it is still frequently used by surgeons [6]. This serves as the main reason why a detailed and comprehensive evaluation of the radial nerve in this area is necessary.

Arora S et al. performed dissections on 10 cadavers and collected surgical data from 60 patients (30 patients and 30 controls) during the posterior approach. The mean distance of the radial nerve from the TA apex was 2.5 cm. They also correlated it with the patient's height and arm length. Their study showed that the distance of the radial nerve from the TA apex is identical in both the cadaver and patient groups [5]. Prasad M et al. studied arms using the cadaveric dissection method. They found that the distance between the radial nerve and the apex point of confluence was 39.7 ± 11.8 mm [6].

Chou PH et al. compared the radial nerve in Chinese and Caucasian adults, which showed significant differences that might be responsible for these variations. The parameters that differed from Caucasians were the distances from the acromion to the upper margin (147 ± 21 mm versus 124 ± 12 mm), the acromion to the lower margin (195 ± 36 mm versus 176 ± 17 mm), and the medial epicondyle to the lower margin (111 ± 21 mm versus 131 ± 10 mm) [10].

Chaudhry T et al. dissected limbs to study the position of the radial nerve with respect to the lateral epicondyle but found considerable variability in the nerve's position. However, they consistently found that the nerve passed adjacent to the lateral border of TA at a distance of 22-27 (± 2 mm). They did not find a radial nerve closer than 13 ± 1 mm to the aponeurosis, so this could be considered a safe area [11]. Few variations in different studies may be due to different races and ethnicities.

Diversity in morphometric measurements and morphology of the triceps aponeurosis (TA) is not uncommon [12]. Many studies reviewed by the authors have focused extensively on the relationship between the radial nerve and TA, but they have not explored these morphological variations, except for Patra A et al. [7]. Patra studied the morphological variations of TA in 60 dissected arms and proposed a new classification with four patterns. In their study, Pattern or Type-I was the most common, accounting for 76.67%, followed by Type-II at 18.33%, Type-III at 3.33%, and Type-IV at 1.67%. These findings from Patra A et al. are consistent with the present study. Any variation in the shape of TA's apex can potentially affect the "safe zone" for dissecting the radial nerve in the posterior approach during surgery [7].

In another study by Patra A et al., the distance of the radial nerve from the apex was highest in Pattern-III, followed by Pattern-I, and least in Pattern-II [Table/Fig-6]. The length and breadth of TA also exhibited variations among the patterns but did not have any impact on determining the "safe zone." These factors may, however, influence the use of TA as a graft. Only one author has correlated values between males and females [7]. Patra A et al. examined 30 cadavers, including 23 males and 7 females. The mean distance from the apex of the aponeurosis to the radial nerve was 3.58 cm in males and 3.54 cm in females. Type-1 pattern was

more common in both males and females (73.91% and 85.71%, respectively). The percentage distribution of TA patterns did not show any gender difference [7].

Distance of radial nerve from TA	Type-I	Type-II	Type-III
Patra A et al., (N=60) [6]	16.3 cm	16.1 cm	17.6 cm
Present study (N=40)	30.44 ± 4.15 mm	31.87 ± 4.2 mm	36.87 ± 0.81 mm

[Table/Fig-6]: Comparison of distance of radial nerve from TA in different types [7].

The Triceps Aponeurosis Tongue Approach (TATA) has gained recent attention due to its excellent results in 87% of patients with intercondylar fractures of the distal humerus [8]. In such cases, knowledge and understanding of TA morphometry and morphology play a crucial role for surgeons [13,14]. Several cadaveric studies have described the relationship between the radial nerve and soft tissue landmarks, such as the apex of the triceps aponeurosis, triceps tendon, and the point of confluence [Table/Fig-7] [5,7,9,15].

Study	N	Study population/Place	Distance RN to the apex of TA
Seigerman DA et al., [15]	30	American/New Jersey	39.0 ± 2.1 mm
Hasan SA et al., [9]	33	American	2.3 ± 1.7 cm
Arora S et al., [5]	60	Indian/North India	2.51 ± 0.2 cm
Patra A et al., [7]	60	Indian/North India	3.57 ± 0.19 cm
Present study	40	Indian/South India	$31.25 \pm$ mm

[Table/Fig-7]: Relationship of radial nerve with apex of tricipital aponeurosis [5,7,9,15].

Limitation(s)

The authors were unable to compare the findings between genders due to the small number of female cadavers (15 males and five females).

CONCLUSION(S)

The TA may vary in shape, length, and breadth. Prior knowledge of these variations is essential for orthopedic surgeons when approaching the humerus posteriorly to avoid iatrogenic injuries to the radial nerve.

Acknowledgement

All the authors sincerely thank the dissection attendants who assisted them during the dissection. The authors also extend their gratitude to all the body donors for their selfless act, without which the present study would not have been possible.

REFERENCES

- [1] Schoch BS, Padegimas EM, Maltenfort M, Krieg J, Namdari S. Humeral shaft fractures: National trends in management. *J Orthop Traumatol.* 2017;18(3):259-63.
- [2] Huttunen TT, Kannus P, Lepola V, Pihlajamäki H, Mattila VM. Surgical treatment of humeral-shaft fractures: A register-based study in Finland between 1987 and 2009. *Injury.* 2012;43(10):1704-08.
- [3] McCormack RG, Brien D, Buckley RE, McKee MD, Powell J, Schemitsch EH. Fixation of fractures of the shaft of the humerus by dynamic compression plate or intramedullary nail: A prospective randomized trial. *The Journal of Bone and Joint Surgery British Volume.* 2000;82-B(3):336-39. Doi: 10.1302/0301-620X.82B3.0820336.
- [4] Schwaiger K, Abed S, Russe E, Koeninger F, Wimbauer J, Kholosy H, et al. Management of radial nerve lesions after trauma or iatrogenic nerve injury: Autologous grafts and neurolysis. *J Clin Med.* 2020;9(12):3823. Doi: 10.3390/jcm9123823.
- [5] Arora S, Goel N, Cheema GS, Batra S, Maini L. A method to localize the radial nerve using the 'Apex of Triceps Aponeurosis' as a landmark. *Clin Orthop Relat Res.* 2011;469(9):2638-44.
- [6] Prasad M, Isaac B, Premkumar PS. Anatomic landmarks to identify the radial nerve during the posterior approach of the humerus: A cadaveric study. *Journal of Clinical & Diagnostic Research.* 2018;12(11):AC01-AC04.
- [7] Patra A, Asghar A, Ravi KS, Duparc F, Arora S. The morphological and morphometric analysis of the variant patterns of the tricipital aponeurosis: A new anatomical classification with possible clinical implications. *Folia Morphologica.* 2022;81(4):1022-30.

- [8] Dev DB. Results of triceps aponeurosis tongue approach for distal humerus fractures. *J Med Sci Clin Res.* 2019;7(4):134-37. Doi: 10.18535/jmscr/v7i4.25.
- [9] Hasan SA, Rauls RB, Cordell CL, Bailey, MS, Nguyen T. "Zone of Vulnerability" for Radial Nerve Injury: Anatomic Study. *Journal of Surgical Orthopaedic Advances.* 2014;23(2):105-10.
- [10] Chou PH, Shyu JF, Ma HL, Wang ST, Chen TH. Courses of the radial nerve differ between Chinese and Caucasians: Clinical applications. *Clin Orthop Relat Res.* 2008;466(1):135-38.
- [11] Chaudhry T, Noor S, Maher B, Bridger J. The surgical anatomy of the radial nerve and the triceps aponeurosis. *Clin Anat.* 2010;23(2):222-26.
- [12] Standring S. *Gray's Anatomy: the anatomical basis of clinical practice.* 41st ed. Edinburg: Churchill Livingstone/Elsevier. 2016. Pp. 783.
- [13] McCann PA, Smith GC, Clark D, Amirfeyz R. The tricipital aponeurosis-a reliable soft tissue landmark for humeral plating. *Hand Surgery.* 2015;20(01):53-58.
- [14] Guse TR, Ostrum RF. The surgical anatomy of the radial nerve around the humerus. *Clinical Orthopaedics and Related Research.* 1995;320:149-53.
- [15] Seigerman DA, Choung EW, Yoon RS, Lu M, Frank MA, Gaines LRJ, et al. Identification of the radial nerve during the posterior approach to the humerus: A cadaveric study. *J Orthop Trauma.* 2012;26(4):226-28.

PARTICULARS OF CONTRIBUTORS:

1. Associate Professor, Department of Anatomy, Dr Chandramma Dayananda Sagar Institute of Medical Education and Research, DSU, Bengaluru, Karnataka, India.
2. Tutor, Department of Anatomy, Dr Chandramma Dayananda Sagar Institute of Medical Education and Research, DSU, Bengaluru, Karnataka, India.
3. Associate Professor, Department of Anatomy, Sri Madhusudan Sai Institute of Medical Sciences and Research, Bengaluru, Karnataka, India.

NAME, ADDRESS, E-MAIL ID OF THE CORRESPONDING AUTHOR:

Dr. B Anisha,
Associate Professor, Department of Anatomy, CDSIMER, Devarakaggalahalli,
Harohalli, Hobli, Bengaluru-562112, Karnataka, India.
E-mail: dranisha10@gmail.com

PLAGIARISM CHECKING METHODS: ^[Jain H et al.] **ETYMOLOGY:** Author Origin

- Plagiarism X-checker: Mar 31, 2023
- Manual Googling: Jun 30, 2023
- iThenticate Software: Jul 03, 2023 (21%)

EMENDATIONS: 6**AUTHOR DECLARATION:**

- Financial or Other Competing Interests: None
- Was Ethics Committee Approval Obtained for this study? Yes
- Was informed consent obtained from the subjects involved in the study? Yes
- For any images presented appropriate consent has been obtained from the subjects. Yes

Date of Submission: **Mar 30, 2023**Date of Peer Review: **May 10, 2023**Date of Acceptance: **Jul 04, 2023**Date of Publishing: **Sep 01, 2023**